

Clinical and ultrasonographic findings, diagnosis and treatment of pyelonephritis in 17 cows

U. Braun ^{a,*}, K. Nuss ^a, D. Wehbrink ^a, S. Rauch ^a, A. Pospischil ^b

^a Department of Farm Animals, University of Zurich, Winterthurerstrasse 260, CH-8057 Zurich, Switzerland

^b Institute of Veterinary Pathology, University of Zurich, Winterthurerstrasse 260, CH-8057 Zurich, Switzerland

Accepted 22 December 2006

Abstract

The goal of the present study was to describe the clinical, haematological and ultrasonographic findings and treatment of 17 cattle with pyelonephritis. Fifteen cattle had an abnormal general condition, which varied in severity; five animals had signs of colic. The urine was brownish-red in 11 animals and cloudy in 13. Clumps of purulent material were seen in the urine of nine animals and clots of blood in two. The specific gravity was lower than normal in 13 animals and ranged from 1.005 to 1.020. A urine test strip revealed protein in 16 animals, blood in 16 and leukocytes in 12. Bacteriological examination of urine yielded *Corynebacterium renale* in 11 animals, *Arcanobacter pyogenes* in two and *Escherichia coli* in one. Rectal examination revealed abnormalities of the urinary tract in 11 animals; there was dilatation of the left ureter and/or enlargement of the left kidney in eight cases, and dilatation of the right ureter and/or enlargement of the right kidney in three others. The most frequent abnormal haematological finding was an increase in the serum concentrations of total protein, fibrinogen, urea and creatinine, a decreased haematocrit and a positive glutaraldehyde test. In 13 animals, ultrasonography via the rectum and right flank using a 5.0 MHz transducer revealed dilatation of the right or left ureter, cystic lesions in one or both kidneys and dilatation of the renal sinus.

Eight animals were euthanased or slaughtered at the owners' request or because of a poor prognosis. Nine (53%) animals were successfully treated; five received antibiotics and four underwent unilateral nephrectomy and antibiotic therapy. The treated animals were clinically healthy when discharged from the clinic 10–21 days after admission. A follow-up via telephone 8–24 months later revealed that none had experienced complications and all were in full production. In cattle with severe unilateral pyelonephritis, unilateral nephrectomy is the treatment of choice.

© 2007 Elsevier Ltd. All rights reserved.

Keywords: Cattle; Pyelonephritis; Clinical findings; Ultrasonography; Treatment

1. Introduction

Pyelonephritis is a specific bacterial infection of the urinary tract in cattle. It has a protracted course and is characterised by fever, episodes of colic and pyuria and/or haematuria (Gründer, 2002). Of bovine kidneys examined, the incidence of pyelonephritis in two abattoir surveys was 0.87% (Rosenbaum et al., 2005) and 3.5% (Monaghan and Hannan, 1983). In a retrospective study, 2/800 bovine patients (0.25%) admitted to a veterinary

teaching hospital were diagnosed with pyelonephritis (Divers et al., 1982).

In the majority of cattle, pyelonephritis is caused by *Corynebacterium renale*, a facultative pathogen that is a common inhabitant of the lower urogenital tract of healthy cattle. *Escherichia coli*, *Arcanobacter pyogenes*, *Corynebacterium cystitidis*, *Corynebacterium pilosum*, *Staphylococcus* spp., *Streptococcus* spp., *Enterococcus* spp., *Klebsiella* spp. and *Pseudomonas* spp. are less commonly isolated from the urine of affected cattle (Fetcher, 1985; Rosenbaum et al., 2005). Pyelonephritis is seen almost exclusively in cows, and in approximately 75% of cases occurs after abortion, dystocia or puerperal infection. Catheterisation of the

* Corresponding author. Tel.: +41 1 6358241; fax: +41 1 6358904.
E-mail address: ubraun@vetclinics.unizh.ch (U. Braun).

bladder for urine collection can result in pyelonephritis (Radostits et al., 2000), and natural breeding has been hypothesized to be another cause (Radostits et al., 2000).

The clinical signs of pyelonephritis have been described in one study of 15 cattle (Rebhun et al., 1989) and in various case reports (Johnson et al., 1984; Wallace et al., 1990; Tyler et al., 1991; Hayashi et al., 1994; Hirsbrunner et al., 1996; Gufler, 1999; Rademacher, 2005). Diagnosis is based on the results of clinical examination and urinalysis as well as ultrasonographic findings (Gründer, 2002; Radostits et al., 2000). Descriptions of the ultrasonographic findings of cows with pyelonephritis have been limited to case reports, in which the findings varied greatly (Tyler et al., 1991; Hayashi et al., 1994; Hirsbrunner et al., 1996; Gufler, 1999; Rademacher, 2005). Hayashi et al. (1994) reported dilatation of the renal pelvis and renal or urethral concretion. In one cow with pyelonephritis, endoscopy of the bladder revealed that the flow of urine, which contained blood and pus, from the affected kidney was only about one-third of that of the normal kidney (Hirsbrunner et al., 1996). Endoscopy was diagnostically useful and warrants further investigation.

Treatment of pyelonephritis necessitates the administration of antibiotics for 10 days to several weeks (Rebhun et al., 1989; Radostits et al., 2000; Gründer, 2002; Van Metre and Divers, 2002) and procaine penicillin is the antibiotic of choice. Treatment of pyelonephritis that is caused by Gram-negative bacteria depends on the results of urine culture and sensitivity; ampicillin, amoxicillin, sulfonamides, gentamycin, and nitrofurans are commonly used. Nephrectomy is advocated in cows with unilateral pyelonephritis that fails to respond to treatment (Horney and Archibald, 1961; Pouden et al., 1962; Tulleners et al., 1981; Johnson et al., 1984; Hayashi et al., 1994; Hirsbrunner et al., 1996). It is crucial to determine that the remaining kidney is healthy before surgery. The goal of the present study was to describe the clinical, haematological and ultrasonographic findings and treatment in 17 cows with pyelonephritis.

2. Materials and methods

2.1. History

From 1987 to 2005, 17 cattle (13 cows, three heifers, one bull calf) with pyelonephritis were examined. They comprised 11 Braunvieh, three Holstein Friesians, two Simmentals and one Aberdeen Angus and were aged six months to 12 years (mean [SD] 5.5 [3.48] years).

Two cows had calved within 2 weeks and two others within 8 weeks of referral. Eight cows had calved >8 weeks before referral, three had never calved and the date of parturition was unknown in two others. Of nine cows in which parturition was observed, one had dystocia. Two cows had undergone repeated treatment for a retained placenta, and one other had been treated for a vaginal injury. Two cows that had calved >6 months before referral had been bred naturally or artificially several times. The bull calf and one of the heifers had been treated for purulent omphalitis.

Eleven animals had been ill 1–8 days and six others for >14 days before referral. The owners of nine animals saw signs of colic, such as treading, lying down and kicking at the abdomen. Tentative diagnoses made by the referring veterinarians were urinary tract disease in 12 animals with brown or bloody urine, indigestion in one case, omphalitis in the bull calf, bronchopneumonia in one case, caecal dilatation in one case and ileus of the small intestines in one case; the latter two animals had signs of colic and had not passed any faeces.

2.2. Physical examination

All cattle underwent a thorough physical examination (Rosenberger, 1979), which included general behaviour and condition, auscultation of the heart, lungs, rumen and intestine, measurement of heart rate, respiratory rate and rectal temperature, swinging auscultation and percussion auscultation of both sides of the abdomen, rectal examination and examination of the faeces. Testing for foreign bodies in the reticulum consisted of pinching of the withers, upward pressure on the xiphoid area and percussion of the reticulum.

2.3. Haematological and biochemical analyses

The haematocrit, total leucocyte count and concentrations of total protein and fibrinogen were determined in EDTA blood. The concentrations of urea and creatinine were determined in serum using a Cobas Integra 700 analyser (Roche Diagnostics) and Roche reagents under conditions defined by the International Federation of Clinical Chemists at 37 °C. Blood gas analysis was undertaken on a jugular venous blood sample and included measurement of pH, pCO₂, bicarbonate and base excess. The reference ranges for the variables were determined in the Veterinary Medical Laboratory, University of Zurich, using blood samples from 10 healthy Swiss Braunvieh cows. Additionally, a glutaraldehyde test (Glutaltest, Gräub) was performed.

2.4. Urinalysis

Urine samples were evaluated for colour, transparency, odour and the presence of abnormal substances. The urine was also assessed using a strip test (Combur⁹-Test, Roche), and the specific gravity was measured using a refractometer. Smears of the urine sediment were stained with Gram stain and examined microscopically, and a urine sample was cultured bacteriologically on blood agar, Brolac agar and MacConkey agar for 24 h at 37 °C. If Gram-negative bacteria were found an antibiogram was performed.

2.5. Ultrasonography of the urinary tract

In 13 of the animals, transrectal ultrasonography of the left kidney, left ureter and bladder was carried out using a

5.0 MHz linear transducer (Hitachi Medical Systems; Braun, 1993). The right kidney and right ureter were examined via transcutaneous ultrasonography from the right flank (Braun, 1991).

2.6. Treatment and outcome

Eight animals were either slaughtered or euthanased without treatment at the owners' request (Nos. 6, 7, 11) because of bilateral pyelonephritis (3, 12, 17) or because of multiple diseases (9, 15). Five animals were treated with antibiotics (2, 5, 10, 13, 14) at the owner's request or because there were only mild or no rectal changes, and four animals underwent unilateral nephrectomy (1, 4, 8, 16) because they had not responded to antibiotic therapy or because severe unilateral pyelonephritis was diagnosed based on clinical and ultrasonographic findings. For details of antibiotic therapy see Section 3.

Surgery was performed either from the left (one animal) or right flank (three animals) (Hooper and Taylor, 1995; Fubini, 2004). The first animal was operated on in left lateral recumbency under general anaesthesia, and the other three were standing using proximal paravertebral local anaesthesia. For the right kidney, a 25-cm incision was made 2 cm caudal and parallel to the last rib. For the left kidney, a straight incision was made in the mid-paralumbar fossa. The retroperitoneal space was entered, and the perirenal fat tissue was bluntly dissected to get access to the kidney. The kidney was freed from fat tissue and adhesions. The renal artery and vein and the ureter were identified by palpation and freed from fat tissue. First the artery, and then the vein were double ligated, and then transected. The suture material for the ligation varied with the surgeon's preference, and No. 7 chromic catgut and No. 6 coated polyglycolic acid were used. The kidney was elevated out of the incision and the ureter was ligated and transected. In case of an inflammation, the ureter was transected close to its junction with the bladder. If there were adhesions or perirenal infection, the ventral part of the incision was left open to allow drainage and second intention healing.

2.7. Post-mortem examination

A post mortem examination was carried out on the kidneys of the animals that were slaughtered, euthanased or underwent surgery.

2.8. Statistical analysis

The data were analysed statistically by the methods of Norusis (1990). The frequencies, means and standard deviations of various variables were calculated. ANOVA was used to compare the rectal temperature, heart rate, respiratory rate and all the blood variables of animals that were slaughtered or euthanased with those of animals that were

treated. The same variables were compared between animals with unilateral and bilateral pyelonephritis.

3. Results

3.1. Clinical findings

An abnormal general condition, which varied in severity, and anorexia or reduced appetite were seen in 15 animals. Five animals were restless and had signs of colic, such as treading, kicking at the abdomen, tail switching and sinking of the back. The heart rate was higher than normal in six animals (84–104 bpm), and the respiratory rate was increased in three (36–44 breaths/min). The rectal temperature was decreased in two animals (38.0 °C) and increased in five others (39.1–40.3 °C). Animals with unilateral pyelonephritis had a significantly higher heart rate (86.3 [14.2] bpm) than those with bilateral pyelonephritis (70.6 [7.5] bpm, $P < 0.05$). The respiratory rate was significantly higher in animals that were slaughtered or euthanased (32.0 [8.0] breaths/min) than those that were successfully treated (24.4 [5.5] breaths/min, $P < 0.05$). Six animals had decreased skin turgor, four had uraemic breath, three had bilateral enophthalmus, two had dry muzzles and one had bruxism. The body condition was moderate to thin in ten animals, and the body surface was cooler than normal in seven. Six animals had moderate to severe scleral injection. The oral mucous membranes were pale in three animals and hyperaemic in two, and the capillary refill time was >2 s in seven animals.

Rumen motility was decreased or absent in 16 animals, and intestinal motility was reduced or absent in eight animals. One or more tests for reticular foreign bodies were positive in seven animals. The abdominal wall was tense in eight animals. Swinging auscultation on the right side was positive in one cow and percussion auscultation was positive on the right side in another; both these tests were positive in two other animals. There was decreased or no faecal output in seven animals. The faeces were porridge-like in three animals, contained mucus in two and were watery in one animal.

Micturition was normal in 14 animals. Two cows voided small amounts of urine in a thin stream, and one cow had stranguria. The urine was reddish-brown in 11 animals, cloudy in 13 cases, and contained pus in nine animals and blood clots in two. The urine had a foul pungent odour in five animals. The specific gravity was decreased and ranged from 1.005 to 1.020 in 13 animals. The pH of the urine was decreased in three cases and increased above normal in five others. A urine strip test revealed an increased amount of protein in 16 animals, blood in 16, leukocytes in 12, glucose in one, ketones in one and nitrite in one animal. Bacteriological culture of the urine yielded *C. renale* in 10 animals, *A. pyogenes* in one and *E. coli* in one. In one other cow, both *C. renale* and *E. coli* were isolated. Rectal examination of the 15 adult

animals revealed abnormalities in the urinary tracts of 11 (Table 1). In eight cows, there was dilatation of the left ureter and/or enlargement of the left kidney. In three cows, there was dilatation of the right ureter and/or enlargement of the right kidney. The palpation of the kidneys and ureters was not painful.

3.2. Haematological and biochemical findings

The concentration of total protein was higher than normal (81–120 g/L) in all the animals, and that of fibrinogen was increased (8–16 g/L) in 16 cases. The glutaraldehyde test was reduced (1–6 min) in 16 animals. The haematocrit

Table 1

Rectal findings, urinalysis, serum urea and creatinine concentrations, ultrasonographic findings, treatment and outcome in 17 cattle with pyelonephritis

| No. | Clinical findings | Urinalysis | Urea/ creatinine | Ultrasonographic findings | Treatment/outcome |
|-----|--|---|---------------------|--|---|
| 1 | Dilation of left ureter and kidney | Urine brownish-red and cloudy, with clumps of pus SG = 1016, +++ PU +++ LU +++ HU, <i>C. renale</i> | U 11.8 C 258 | NE | Successful nephrectomy of the left kidney |
| 2 | Dilation of left ureter and kidney | Urine cloudy with clots of pus, SG 1015, + PU, +++ LU, +++ HU, <i>C. renale</i> | U 6.6 | NE | Treatment with procaine penicillin successful |
| 3 | NE (only 7 months old) | ++ PU, + LU, +++ HU, <i>C. renale</i> and <i>A. pyogenes</i> | U 35.9 | NE | Slaughter: bilateral pyelonephritis, cystitis, omphalitis, urachal abscess |
| 4 | Dilation of left ureter and kidney | Urine brownish-red and cloudy, SG 1008, ++ LU, +++ HU | U 6.4 C 173 | Renal sinus of left kidney hyperechogenic | Successful nephrectomy of the left kidney |
| 5 | No abnormal rectal findings | Urine brownish-red, cloudy and foul-smelling, SG 1015, ++ PU, ++ LU, +++ HU, <i>C. renale</i> | U 5.0 C 93 | No abnormal findings | Treatment with procaine penicillin successful |
| 6 | Dilation of left ureter and kidney | Urine cloudy, ++ PU, +++ LU, ++ HU, <i>C. renale</i> | U 4.0 C 138 | Renal sinus of left kidney and left ureter dilated | Slaughter: pyelonephritis of the left kidney |
| 7 | No abnormal rectal findings | +++ PU, +++ LU, + HU | U 7.9 C 160 | NE | Slaughter: pyelonephritis of the right kidney |
| 8 | Dilation of right ureter | Urine brownish-red, cloudy and foul-smelling, SG 1007, + PU, +++ LU, +++ HU, <i>E. coli</i> | U 11.9 C 129 | Cystic lesions in right kidney | Successful nephrectomy of the right kidney |
| 9 | NE (only 5 months old) | SG 1009, + PU, +++ HU, <i>E. coli</i> | U 3.1 C 89 | Cystic lesions in right kidney | During laparotomy for omphalitis and urachal abscess diagnosis of pyelonephritis of the right kidney and euthanasia |
| 10 | Left kidney enlarged | Urine brownish-red and cloudy with clumps of pus, SG 1010, + PU, +++ HU, ++ LU, <i>C. renale</i> | U 17.2 C 236 | Marked decrease in size of renal pyramids of the left kidney, several echogenic foci in the right kidney | Successful treatment with a combination of trimethoprim, sulfadimidine and sulfathiazole |
| 11 | No abnormal rectal findings | Urine brownish-red and cloudy with clumps of pus and blood clots, SG 1009, +++ PU, + LU, +++ HU, <i>C. renale</i> | U 264 C 306 | Cystic lesions in right kidney | Euthanasia: pyelonephritis of the right kidney |
| 12 | Dilation of left kidney and left ureter | Urine brownish-red and cloudy with clumps of pus, +++ PU, +++ HU, <i>A. pyogenes</i> | U 29.5 C 1180 | Both kidneys enlarged, left ureter dilated | Slaughter: bilateral pyelonephritis |
| 13 | No abnormal rectal findings | Urine brownish-red and cloudy, SG 1010, ++ PU, +++ HU, <i>C. renale</i> | U 16.0 C 248 | No abnormal findings | Successful treatment with amoxicillin (18 days) |
| 14 | Both ureters dilated | Urine with clumps of pus, SG 1050, + PU, +++ HU, <i>C. renale</i> | U 6.9 C 105 | Both kidneys dilated, renal sinus of both kidneys dilated | Successful treatment with oxytetracycline (7 days) |
| 15 | Pyometra (diagnosed by rectal and vaginal examination) | SG 1008, + PU, no bacteriological examination of urine | U 7.6 C 95 | Cystic lesions in right kidney | Slaughter because of pyometra: pyometra and bilateral pyelonephritis, <i>A. pyogenes</i> isolated in uterus and kidneys |
| 16 | Dilation of right ureter and right kidney | Urine brownish-red and cloudy with clumps of pus, foul-smelling, SG 1017, ++ PU, + LU, +++ HU, <i>C. renale</i> | U 10.8 C 117 | Dilation of left ureter and left kidney | Successful nephrectomy of the left kidney from the left flank |
| 17 | Dilation of left ureter | Urine brownish-red and cloudy with clumps of pus, SG 1017, ++ PU, + LU, +++ HU | U 11.3 C 133 | Dilation of right kidney and right renal sinus, dilation of left ureter | Slaughter: bilateral pyelonephritis |

U, urea (mmol/L); C, creatinine (μmol/L); NE, not examined; HR, heart rate; RT, rectal temperature; SG, specific gravity of urine; PU, proteinuria; LU, leukocyteuria; HU, haematuria.

was lower than normal (17–26%) in 11 animals, and the concentrations of urea and creatinine were elevated in 11 (7.6–35.9 mmol/L) and nine animals (129–1180 µmol/L), respectively. Venous blood gas analysis revealed a mild decrease in blood pH (7.30–7.35) in three cows. Eight cows with a normal blood pH had an increased base excess (2.4–12.3 mmol/L; compensated metabolic alkalosis). The haematocrit of animals that were slaughtered was significantly lower (23.5 [3.6]%) than that of animals that were successfully treated (28.4 [4.30]%, $P < 0.05$). The concentration of urea in animals with unilateral pyelonephritis (7.8 [3.4] mmol/L) was significantly lower than that of animals with bilateral disease (19.3 [11.5] mmol/L, $P < 0.05$). The values of the former ranged from 3.1 to 11.8 mmol/L and the latter from 6.9 to 35.9 mmol/L (Fig. 1).

3.3. Ultrasonographic findings (Table 2)

Eight animals were diagnosed ultrasonographically as unilaterally (4, 6, 8, 9, 10, 11, 15, 16) and three as bilaterally (12, 14, 17) affected (Table 2). In two animals, the kidneys appeared normal (5, 13). The main ultrasonographic find-

ings were dilatation of the left or right ureter (Fig. 2) in seven animals, cystic lesions in one or both kidneys (Fig. 3) in four and dilatation of the renal sinus (Fig. 4) in three animals. The renal sinus of the affected kidney was hyperechogenic in one case, the medullary pyramids were conspicuously small in another and one animal had several echogenic foci with acoustic shadows as well as multiple fluid-filled cavities in the affected renal sinus/kidney. Two animals had bilateral enlargement of both kidneys, although there were no ultrasonographic abnormalities.

3.4. Outcome

Eight animals were slaughtered or euthanased at the owners' request or because of a tentative diagnosis of severe bilateral pyelonephritis and a grave prognosis. The remaining nine (53%) animals were successfully treated with antibiotics (five) or unilateral nephrectomy (four). The latter had not responded to antibiotic therapy and severe unilateral pyelonephritis was suspected based on clinical and ultrasonographic findings. Thus, surgical removal of the left kidney in three and the right kidney in one animal was undertaken. The surgical approach was from either the left (one animal) or right flank (three animals).

The nine treated animals received one of the following antibiotic therapies for 6–28 days: 15,000 IU/kg procaine penicillin (Procaine-Penicillin G, Pfizer), administered intramuscularly (IM) every 8 h; 7 mg/kg amoxicillin (Clamoxyl, SmithKline Beecham), administered IM once daily; 10 mg/kg oxytetracycline (Engemycin, Intervet Intern), administered intravenously (IV) once daily; 16 mg/kg of a combination of trimethoprim, sulfadiazole and sulfathiazole (Vetoprim 24%, Essex), administered IV once daily. All animals were treated with 10 L of sodium and glucose solution (50 g glucose and 9 g sodium chloride/L) administered IV in a slow drip, daily for 2–6 days. The five animals treated with antibiotics alone received three boluses of a combination of nitrofurantoin and metamizole (Urofur, Chassot), administered orally once daily for 3–20 days. Three of the operated animals received 500 mg of flunixin meglumine (Finadyne, Essex), administered IV once daily for 3 days. Within a few days of surgery, the macroscopic appearance of the urine (Fig. 5) and the general condition of the animals returned to normal. The animals treated with antibiotics alone had a similar but longer course of recovery. All treated animals were clinically healthy and discharged from the clinic 10–21 days after admission. A follow-up via telephone 8–24 months later revealed that all nine animals had returned to full production and had experienced no complications.

3.5. Post-mortem findings

In eight of the animals that were euthanased or slaughtered, five had bilateral pyelonephritis and three had

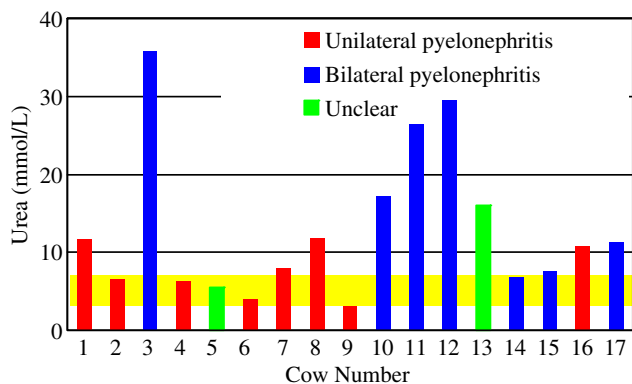


Fig. 1. Serum concentration of urea in cattle with unilateral or bilateral pyelonephritis. The yellow bar represents the normal range.

Table 2
Results of ultrasonographic examination of the urinary tract of 13 cattle with pyelonephritis

| Organ | Ultrasonographic findings | Number of cows |
|--------|--|----------------|
| Ureter | Dilated ureter (left side, 5; right side, 2) | 7 |
| Kidney | Cystic lesions in kidney (left kidney, 1; right kidney, 3) | 4 |
| | Dilated renal sinus (left kidney, 2; right kidney, 1) | 3 |
| | Hyperechogenic renal sinus (left kidney) | 1 |
| | Marked decrease in size of renal pyramids (left kidney) | 1 |
| | Several echogenic foci with distal acoustic shadows and fluid-filled cavities (right kidney) | 1 |
| | Both kidneys enlarged but no abnormal ultrasonographic findings | 2 |
| | Both kidneys normal | 2 |

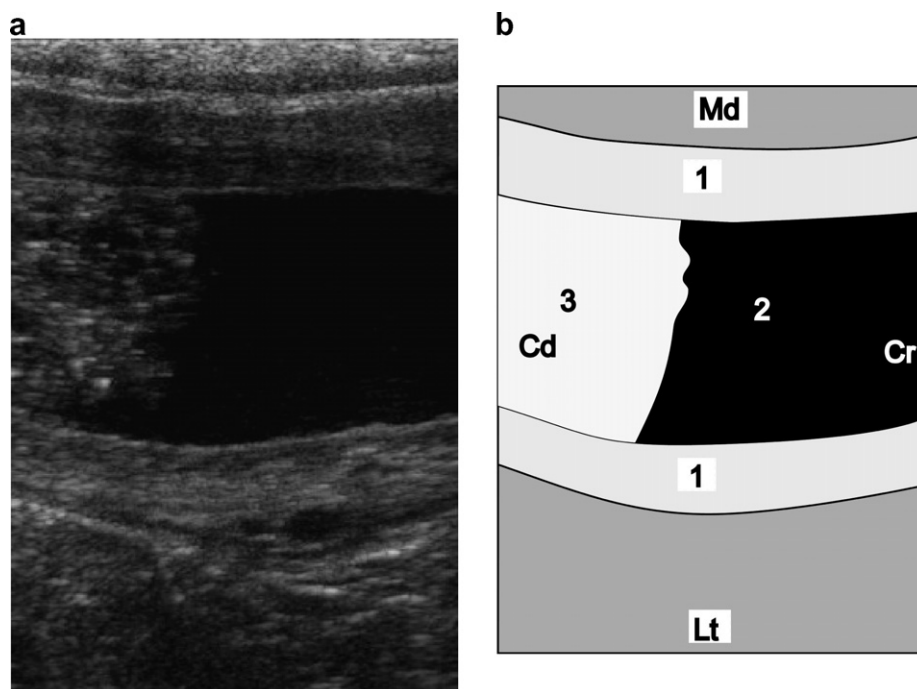


Fig. 2. Ultrasonogram showing dilatation of the left ureter in a cow with pyelonephritis. A longitudinal view of the ureter was obtained via transrectal ultrasonography using a 5.0 MHz linear transducer. The ureter is markedly dilated. The cranial aspect contains anechogenic urine and the caudal part contains inflammatory material, which is obstructing the ureter resulting in signs of colic. 1, Thickened wall of ureter; 2, urine in cranial aspect of ureter; 3, inflammatory material in caudal part of ureter; Md, medial; Lt, lateral; Cr, cranial; Cd, caudal.

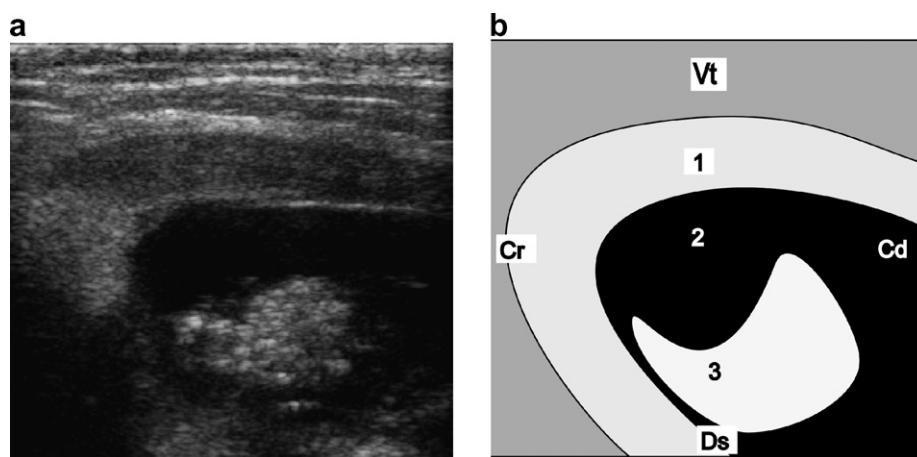


Fig. 3. Ultrasonogram of a renal pyramid containing echogenic material in a cow with pyelonephritis. Transrectal ultrasonography was carried out using a 5.0 MHz linear transducer, which was placed ventral to the left kidney with the beam aimed dorsally. 1, Renal parenchyma; 2, dilated renal pyramid; 3, echogenic material in the renal pyramid; Ds, dorsal; Vt, ventral; Cr, cranial; Cd, caudal.

unilateral pyelonephritis. All of the affected kidneys had severe chronic suppurative and often necrotising pyelonephritis and ureteritis. The kidneys were enlarged and many had multicystic changes. In three animals, there was severe purulent or purulent necrotising cystitis. Suppurative omphalitis, urachal abscess, severe bronchopneumonia, pyometra, multiple Type-I abomasal ulcers and diffuse peritonitis were diagnosed in one animal each.

3.6. Diagnosis

Pyelonephritis was diagnosed in 15/17 animals based on the results of urinalysis, rectal examination and/or ultrasonography. In a heifer with proteinuria and haematuria that underwent surgery for omphalitis and a urachal abscess, pyelonephritis of the right kidney was first diagnosed during laparotomy; the animal was then euthanased. The

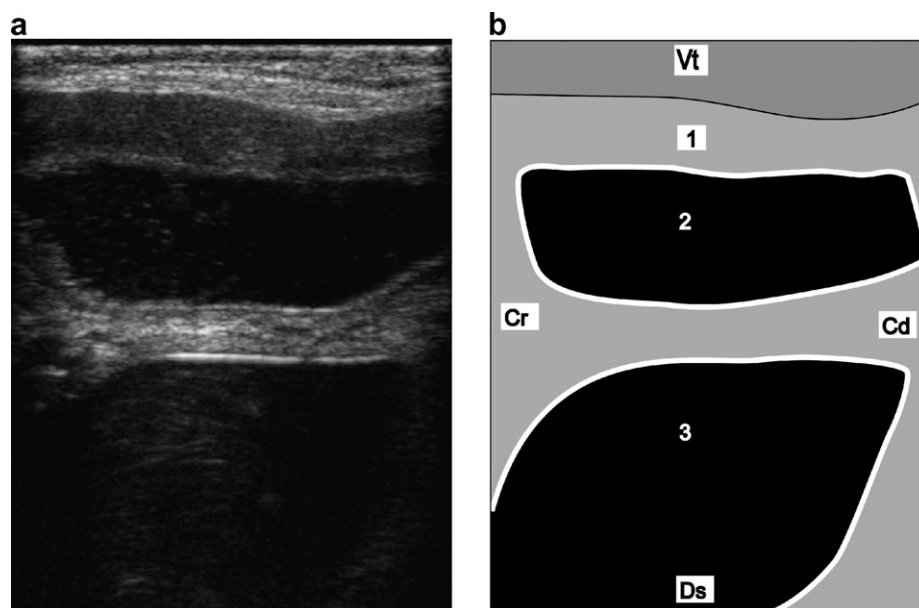


Fig. 4. Ultrasonogram of the renal sinus of a cow with pyelonephritis. Transrectal ultrasonography was carried out using a 5.0 MHz linear transducer, which was placed ventral to the left kidney with the beam aimed dorsally. The renal sinus and a renal pyramid are dilated and the latter contains anechogenic urine. 1, Renal parenchyma; 2, dilated renal pyramid; 3, dilated renal sinus; Ds, dorsal; Vt, ventral; Cr, cranial; Cd, caudal.

results of urinalysis had been incorrectly associated with the urachal problem alone. In one cow with mild proteinuria and isosthenuria and in which pyometra was diagnosed, bilateral pyelonephritis was first found at post mortem examination.

Based on the clinical, ultrasonographic and post mortem findings, bilateral pyelonephritis was diagnosed in seven animals (41%) and unilateral pyelonephritis in eight (47%). In two other animals that were treated with antibi-

otics, it was not known whether pyelonephritis involved one or both kidneys. The left kidney was affected in 12 animals and the right kidney in 10.

4. Discussion

The clinical findings in the present study were in agreement with those of other reports (Johnson et al., 1984; Rebhun et al., 1989; Tyler et al., 1991; Hayashi et al.,




Fig. 5. Bloody urine of a cow with pyelonephritis before unilateral nephrectomy (left side). The urine appears macroscopically normal one week after surgery (right side).

1994; Hirsbrunner et al., 1996; Gufler, 1999; Rademacher, 2005). The main sign in 13 animals was brown or red urine and/or cloudy urine. However, in four animals with severe pyelonephritis, the urine appeared normal, although a test strip revealed moderate to severe haematuria and proteinuria in three of them as well as leucocyturia in another. In one cow with severe bilateral pyelonephritis and concomitant pyometra, mild proteinuria and a urine specific gravity of 1.008 were found. These findings show that macroscopic evaluation of the urine could be used to diagnose urinary tract disease in 76% of the animals and when combined with the results of a strip test was diagnostic in 94% of the animals. In cattle with haematuria or cloudy urine and proteinuria, the differential diagnosis must include bracken fern poisoning, cystitis, urolithiasis and vaginal disease as well as pyelonephritis (Van Metre and Divers, 2002).

Interestingly, two calves, aged 5 and 7 months, had pyelonephritis. In both cases, the cause was suppurative omphalitis, which was associated with a urachal abscess and persistent urachus in the male calf (No. 3) and with an umbilical abscess in the heifer (No. 9).

Comparison of the clinical and pathological findings often yielded surprising results; some animals with severe pathological lesions in the kidneys had only mild changes in the urine. Bilateral pyelonephritis was diagnosed ante-mortem in seven of the animals and unilateral pyelonephritis in eight cases. This contradicts reports that only 10–20% of cattle have unilateral pyelonephritis (Gründer, 2002). It is essential to determine whether one or both kidneys are affected for a prognosis. However, in two cows that were successfully treated with antibiotics, there were no abnormal rectal or ultrasonographic findings, and although *C. renale* was isolated from markedly abnormal urine, it was not known whether there was unilateral or bilateral pyelonephritis. This is not an isolated occurrence because in many cattle with pyelonephritis, the only abnormal finding is urinary changes (Radostits et al., 2000).

The left kidney (12 cases) was slightly more often affected than the right (10 cases). Hayashi et al. (1994) hypothesized that the left kidney is more frequently infected because its ureter is shorter than that of the right kidney. When nephrectomy is considered for treatment, the health of the other kidney must be carefully investigated before the operation. Cystoscopy may be a useful diagnostic aid in this respect; bloody or purulent urine dripping from both ureters into the bladder indicates bilateral disease (Hirsbrunner et al., 1996; Braun et al., 2004).

The results of blood analysis were in agreement with those of other reports on cattle with pyelonephritis (Rebhun et al., 1989; Radostits et al., 2000). The concentration of total protein was increased in all the animals, the concentration of fibrinogen was increased in 16, and 16 had a reduced glutaraldehyde test, all of which are indicative of severe chronic inflammation. In 11 animals, the haematocrit was lower than normal, which may have been attributable to chronic disease, blood loss in the urine or a

decreased production of erythropoietin by the diseased kidneys. Interestingly, the serum concentrations of urea and creatinine were normal in six and eight animals, respectively. The serum concentration of urea was significantly higher in animals with bilateral pyelonephritis than those with unilateral pyelonephritis, although three animals with bilateral disease had only mild elevations in serum urea values. Thus serum concentrations of urea that are normal or mildly elevated are not a reliable indicator of unilateral pyelonephritis. In the present study, a urea concentration of >15 mmol/L was a reliable indicator of bilateral pyelonephritis and, in agreement with the results of a previous study (Fetcher, 1986), is associated with a poor prognosis. It is difficult to explain why two cows with severe bilateral pyelonephritis had normal serum creatinine concentrations and a normal or mild elevation in the serum concentration of urea. However, in both cows, the specific gravity of the urine was lower than normal (1.005 and 1.008), which indicated that it was necessary for these animals to produce a large amount of very dilute urine to excrete urea and creatinine. Presumably, the impairment of renal function involved <75% of the renal tissue, which is considered the cut-off for the development of azotaemia (Tulleners et al., 1981). Blood gas analysis revealed non-specific findings. Blood pH was normal in 12 cows. Similarly as in previous papers (Brobst et al., 1978; Divers et al., 1982) some animals had mild acidosis and some had mild compensated alkalosis.

Ultrasonography is particularly helpful for the diagnosis of pyelonephritis of the right kidney, which cannot normally be palpated transrectally, and to assess the condition of the right kidney in cases scheduled for left-sided nephrectomy. The ultrasonographic appearance of the diseased kidneys was heterogeneous, similar to descriptions in case reports of pyelonephritis (Tyler et al., 1991; Hayashi et al., 1994; Hirsbrunner et al., 1996; Gufler, 1999; Rademacher, 2005). Dilatation of the ureter on the affected side was the most common finding followed by cystic changes within the kidney. These findings are consistent with severe disease but not necessarily indicative of pyelonephritis. Those conditions ruled out included obstructive urolithiasis (Braun et al., 2007) and, in cases with cystic lesions, hydronephrosis.

Before treatment is started, it is important to determine the severity of the disease and whether one or both kidneys are affected. Treatment is not indicated in cattle with severe bilateral pyelonephritis. Nephrectomy is our treatment recommendation for severe unilateral pyelonephritis, particularly in cases that have not responded to antibiotic therapy. The speedy recovery and return to full production in the operated cows was very impressive. Operating on standing patients using paravertebral anaesthesia is considerably easier than having the animal recumbent under general anaesthesia and is, therefore, preferred. In three animals, the left kidney was removed via a right flank incision in the first two and from the left flank in the third. Access to the left kidney proved easier from the left flank and this

approach will be used in the future. The animal should be fasted for 24 h when using a left flank approach to reduce rumen fill.

References

- Braun, U., 1991. Ultrasonographic examination of the right kidney in cows. *American Journal of Veterinary Research* 52, 1933–1939.
- Braun, U., 1993. Ultrasonographic examination of the left kidney, the urinary bladder, and the urethra in cows. *Journal of Veterinary Medicine Series A* 40, 1–9.
- Braun, U., Rütten, M., Högger, R., Germann, S., Nuss, K., 2004. Colic in a cow caused by lymphoma of the urinary bladder. *Veterinary Record* 155, 777–778.
- Braun, U., Nuss, K., Sydler, T., Lischer, C., 2007. Ultrasonographic findings in three cows with ureteral obstruction due to urolithiasis. *Veterinary Record* 159, 750–752.
- Brobst, D.F., Parish, S.M., Torbeck, R.L., Frost, O.L., Bracken, F.K., 1978. Azotemia in cattle. *Journal of the American Veterinary Medical Association* 173, 481–485.
- Divers, T.J., Crowell, W.A., Duncan, J.R., Whitlock, R.H., 1982. Acute renal disorders in cattle: a retrospective study of 22 cases. *Journal of the American Veterinary Medical Association* 181, 694–699.
- Fetcher, A., 1985. Renal disease in cattle. Part I. Causative agents. *Compendium on Continuing Education for the Practicing Veterinarian* 7, S701–S707.
- Fetcher, A., 1986. Renal disease in cattle: Part II. Clinical signs, diagnosis, and treatment. *Compendium on Continuing Education for the Practicing Veterinarian* 8, S338–S344.
- Fubini, S.L., 2004. Surgery of the kidney. In: Fubini, S., Ducharme, N. (Eds.), *Farm Animal Surgery*. Saunders, St. Louis, pp. 419–422.
- Gründer, H.D., 2002. Krankheiten der Harnorgane. In: Dirksen, G., Gründer, H.D., Stöber, M. (Eds.), *Innere Medizin und Chirurgie des Rindes*, fourth ed. Parey Buchverlag, Berlin, pp. 697–736.
- Gufler, H., 1999. Nierenabszesse, Pyelonephritis und Zystitis purulenta bei einem 5 Monate alten Kalb – diagnostiziert mittels Sonographie. *Wiener Tierärztliche Monatsschrift* 86, 247–251.
- Hayashi, H., Biller, D.S., Rings, D.M., Miyabayashi, T., 1994. Ultrasonographic diagnosis of pyelonephritis in a cow. *Journal of the American Veterinary Medical Association* 205, 736–738.
- Hirsbrunner, G., Lang, J., Nicolet, J., Steiner, A., 1996. Nephrektomie nach chronischer, unilateraler, eitriger Pyelonephritis beim Rind. *Tierärztliche Praxis* 24, 17–21.
- Hooper, R.N., Taylor, T.S., 1995. Urinary surgery. *Veterinary Clinics of North America Food Animal Practice* 11, 95–121.
- Horney, D., Archibald, J., 1961. Nephrectomy in cattle and sheep. *Journal of the American Veterinary Medical Association* 138, 551–552.
- Johnson, R., Grymer, J., Gerloff, B., Dunstan, R., 1984. Nephrectomy as treatment for pyelonephritis in a cow. *Compendium on Continuing Education for the Practicing Veterinarian* 6, S356–S359.
- Monaghan, M.L.M., Hannan, J., 1983. Abattoir survey of bovine kidney disease. *Veterinary Record* 113, 55–57.
- Norusis, M.J., 1990. *SPSS/PC+ V4.0. Base Manual for the IBM PC/XT/AT and PS/2*. SPSS Inc, Chicago.
- Pounden, W.D., Krauss, W.E., Hibbs, J.W., 1962. Bovine nephrectomy. *Journal of the American Veterinary Medical Association* 140, 687–688.
- Rademacher, G., 2005. Starke Kolik bei einer Kuh mit Pyelonephritis. *Tierärztliche Umschau* 60, 291–293.
- Radostits, O.M., Gay, C.C., Blood, D.C., Hinchliff, K.W., 2000. Contagious bovine pyelonephritis. In: *Veterinary Medicine. A Textbook of the Diseases of Cattle, Sheep, Pigs, Goats and Horses*, ninth ed. W.B. Saunders, London, pp. 721–723.
- Rebhun, W.C., Dill, S.G., Perdritz, J.A., Hatfield, C.E., 1989. Pyelonephritis in cows: 15 cases (1982–1986). *Journal of the American Veterinary Medical Association* 194, 953–955.
- Rosenbaum, A., Guard, C.L., Njaa, B.L., McDonagh, P.L., Schultz, C.A., Warnick, L.D., White, M.E., 2005. Slaughterhouse survey of pyelonephritis in dairy cows. *Veterinary Record* 157, 652–655.
- Rosenberger, G., 1979. *Clinical Examination of Cattle*. Paul Parey, Berlin.
- Tulleners, E.P., Deem, D.A., Donawick, W.J., Whitlock, R.H., 1981. Indications for unilateral bovine nephrectomy: A report of four cases. *Journal of the American Veterinary Medical Association* 179, 696–700.
- Tyler, J.W., Smith, B.F., Irvine, J., 1991. Hydronephrosis and pyelonephritis associated with an anomalous vas deferens in a bull. *Journal of the American Veterinary Medical Association* 198, 871–872.
- Van Metre, D.C., Divers, T.J., 2002. Urinary tract infection. In: Smith, B.P. (Ed.), *Large Animal Internal Medicine*, third ed. Mosby, St. Louis, pp. 863–866.
- Wallace, L.L.M., Bouchard, G., Nicholson, W., Turk, J., Sweeney, C.L., 1990. Polypoid cystitis, pyelonephritis, and obstructive uropathy in a cow. *Journal of the American Veterinary Medical Association* 197, 1181–1183.